

Medial Patellofemoral Ligament Reconstruction: Docking Technique

Karen J. Boselli, MD,* Andrea L. Bowers, MD,[†] Beth E. Shubin Stein, MD,[†]
and Christopher S. Ahmad, MD*

The management of patellar instability has advanced with an improved understanding of the critical role of the medial patellofemoral ligament (MPFL), along with the development of novel techniques for ligament reconstruction. The docking technique for MPFL reconstruction offers several technical advantages, including anatomically accurate reconstruction, ease of confirmation of graft isometry, and simplicity of graft tensioning and fixation. Biomechanically, the femoral fixation provides a combined interference screw and suture anchor construct. Imbrication of the vastus medialis obliquus (VMO) and medial retinaculum contributes additional dynamic support to the medial soft-tissue reconstruction. The docking technique offers a simplified and accurate approach to MPFL reconstruction, with consistently favorable postoperative results in the management of patellar instability. Oper Tech Sports Med 18:98-106 © 2010 Elsevier Inc. All rights reserved.

KEYWORDS patellofemoral, instability, docking, reconstruction

Patellar instability is a common yet complex disorder, which can be disabling for young individuals.¹ Many elements contribute to patellofemoral stability, which can be conceptually divided into bony and soft-tissue structures. In patients with normal osseous architecture, it is generally accepted that soft-tissue abnormalities are responsible for instability.² Of these soft-tissue structures, the medial patellofemoral ligament (MPFL) has been shown to be the primary restraint to lateral patellar instability,³⁻⁵ with multiple independent biomechanical studies demonstrating that the MPFL accounts for 50%-60% of medial soft-tissue restraining force resisting lateral patellar subluxation.⁶⁻¹¹ Furthermore, in more than 90% of patients, primary dislocation involves an acute disruption of the MPFL.^{3,12-14} Consequently, MPFL injury is considered by many as the essential lesion of patellar instability.^{4,5,12,14,15}

Given the importance of the MPFL as a medial restraint in patellar instability, as well as the frequency of its injury with patellar dislocation, numerous procedures have been developed for the reconstruction of this ligament.¹⁶⁻²¹ Recently,

the technique and results have been described for an MPFL reconstruction that involves docking fixation of a semitendinosus autograft at the patella and interference screw graft fixation at the medial epicondyle of the femur. The procedure allows for precise tunnel placement that maximizes native ligament isometry and simplifies graft tensioning and fixation. Furthermore, the technique includes imbrication of the medial retinaculum and vastus medialis obliquus (VMO), thus incorporating the VMO as a dynamic stabilizer of the patella.²² Finally, the bone tunnel for graft placement on the patella is unicortical, thus minimizing the risk of fracture compared with other techniques that employ more complex cortical tunnel patterns within the patella. This review presents the technique of reconstruction, its rationale, and results.

Anatomy and Biomechanics

The anatomy of the patellofemoral articulation is complex, with both bony and soft-tissue structures playing important stabilizing roles. Proper patellar tracking results from balanced interactions between the soft-tissue stabilizers,²³ both static and dynamic, and small deviations from the state of equilibrium may result in patellar instability.¹ The MPFL and VMO play the most critical roles in static and dynamic patellofemoral stability,¹ with the MPFL serving as the primary static restraint to lateral translation. The VMO is intimately

*Department of Orthopaedic Surgery, Center for Shoulder, Elbow and Sports Medicine, Columbia University Medical Center, New York, NY.

[†]Hospital for Special Surgery, Sports Medicine Service, New York, NY.

Address reprint requests to Christopher S. Ahmad, MD, Department of Orthopaedic Surgery, Center for Shoulder, Elbow and Sports Medicine, Columbia University Medical Center, New York, NY. E-mail: csa4@columbia.edu

associated with the ligament, acting as the primary dynamic medial stabilizer.²³ Additional structures, including the patellomeniscal ligaments, patellotibial ligaments, and medial retinaculum contribute to medial stability to a lesser extent.^{1,6-8} A comprehensive understanding of patellofemoral anatomy and biomechanics has improved operative technique and accuracy of ligament reconstruction, ultimately increasing success rates and decreasing complications.⁶

In addition to understanding the biomechanical contribution of the MPFL, a detailed knowledge of its exact anatomy is important for accurate graft positioning during ligament reconstruction. Specifically, the femoral attachment site is most critical for proper isometry, as even a slight difference in the position of the femoral tunnel can lead to significant changes in length of the ligament during range of motion.^{2,11} The typical consequence of a nonanatomic, and therefore nonisometric femoral tunnel is a graft that is loose in extension and relatively tight in flexion. As a result, the graft may limit full knee flexion and increase load on the patella. Alternatively, knee flexion will force the graft to loosen, resulting in a graft that no longer functions to stabilize the patella.

The exact femoral attachment site of the MPFL is still somewhat controversial, having been described in several different locations.¹¹ The patellar attachment site, however, has been more consistently defined in the literature. Tuxoe et al concluded that the MPFL inserts on the femur just proximal to the insertion of the superficial medial collateral ligament (MCL), and just distal to the insertion of the adductor magnus on the adductor tubercle.¹³ They defined the patellar insertion at the proximal two-thirds of the medial margin of the patella. The authors also noted that the mid portion of the MPFL joined the undersurface of the VMO and aponeurotic fibers of the vastus intermedius.¹³ Conlan et al similarly found the femoral insertion at the adductor tubercle, just proximal to the origin of the superficial MCL.⁶ The MPFL again was seen to insert on the undersurface of the distal aspect of the quadriceps mechanism.⁶ Desio et al demonstrated MPFL femoral attachments to the adductor tubercle, medial femoral epicondyle, and superficial MCL via a superior and inferior decussation.⁷ The authors consistently found the patellar attachment at the superior medial patella. Additionally, in all specimens the deep fascia of the VMO was attached to the MPFL.⁷

Smirk et al examined the anatomy and isometry of the MPFL in cadaveric knees.¹¹ The most consistent femoral attachment site was 10 mm distal and 5 mm posterior to the adductor tubercle, with attachment to the superomedial patella in 88% of patients. This description differs from previously mentioned studies that describe the attachment at the anterior medial epicondyle, adductor tubercle, or superficial MCL.^{6,7,13} Using combinations of 7 different femoral and 3 different patellar attachment sites for ligament reconstruction, the authors found that the correct patellar and femoral attachment site should produce isometric motion patterns up to 80° of knee flexion. Nomura et al similarly found that the femoral MPFL insertion was an oval area at the posterosuperior aspect of the medial epicondyle, 1 cm distal to the adductor tubercle.²⁴ Additionally, they found a consistently in-

timate relationship between the MPFL and VMO, suggesting VMO contraction may act not only as a direct stabilizer of the patella but also as an indirect stabilizer via tightening of the MPFL.²⁴

On the basis of these anatomic findings, the docking technique for MPFL reconstruction incorporates a femoral tunnel placed at the posterior aspect of the medial epicondyle, proximal or sometimes within the superficial MCL, and 1 cm distal to the adductor tubercle. The technique confirms graft isometry before creating the femoral tunnel; if the position is unacceptable, the location of the tunnel is easily adjusted. The patellar bone tunnel is placed at the junction of the superior one-third and inferior two-thirds of the medial aspect of the patella.² Finally, through a horizontal incision in the medial retinaculum, the VMO is imbricated over the reconstructed MPFL, incorporating the quadriceps as a dynamic medial stabilizer of the construct.

The knee flexion angle for graft tensioning and fixation is somewhat controversial; however, tensioning of the graft with the knee flexed to 60° has been supported in the literature through biomechanical work by Nomura et al.¹⁹ The authors demonstrated that the length of the MPFL between the center of the patellar attachment and the center of the femoral attachment is close to its maximum at 0° and 60° of flexion, with graft length decreasing at 90° and 120°. At 0°, however, the patella is not engaged in the trochlear groove, making accurate position difficult to determine intraoperatively. Between 20° and 30° of flexion, the lateral facet of the patella contacts the lateral trochlea, acting as a buttress to lateral translation.¹⁵ At 60° the patella is fully engaged within the trochlea and the MPFL is at its maximum length. Thus, tensioning and fixation of the graft at this knee flexion angle ensures proper length of the ligament.^{19,21}

The choice of graft and graft fixation in the MPFL docking technique is supported by current biomechanical data. The tensile strength of the MPFL in cadaveric knees has been shown to be only 208 N.^{9,25} A doubled semitendinosus autograft has a load to failure of 2330 N,²⁶ and therefore possesses more than adequate strength for standard MPFL reconstruction. With regard to fixation, the use of an interference screw placed perpendicular to the direction of pull of the graft has proven to be effective in recent literature relating to the biceps tendon.^{27,28}

Indications

Patients indicated for MPFL reconstruction have experienced recurrent instability despite a trial of nonoperative treatment, including bracing and physical therapy, in the presence of normal osseous anatomy. MPFL reconstruction is also considered in patients with mild bony malalignment. We do not universally exclude patients with chondral lesions to the medial facet of the patella despite the risk of pain related to increased loads on the lesion; many of these patients are disabled by the recurrent dislocations and still experience improvement with reconstruction. Furthermore, treatment of the chondral injury may be performed in conjunction with the MPFL reconstruction, as detailed in a later article in this

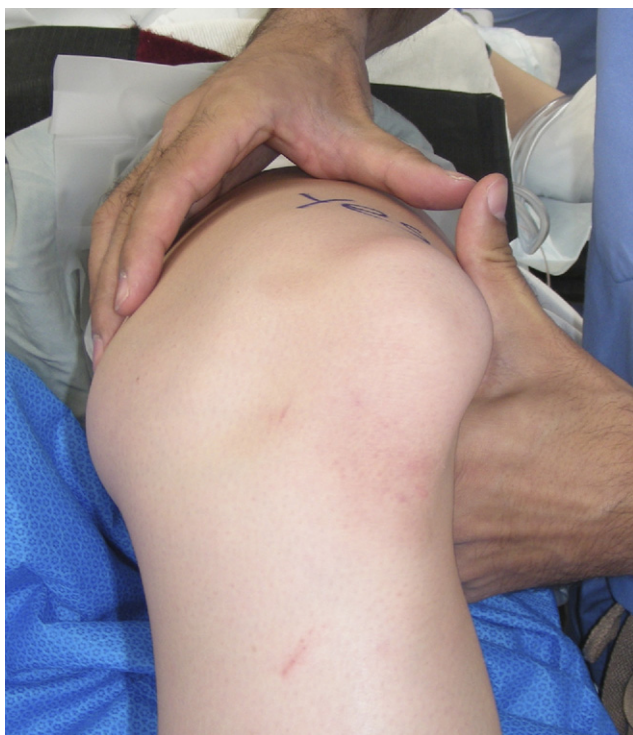

Figure 1 Intraoperative examination under anesthesia demonstrating lateral patellar dislocation with the knee in a flexed position. (Reprinted with permission from Elsevier from G.D. Brown, C.S. Ahmad: The docking technique for medial patellofemoral ligament reconstruction. *Op Tech Orthop* 17:216-222, 2007.)

issue by Slabaugh et al. Contraindications to MPFL reconstruction include extreme malalignment and patellofemoral arthritis.

Surgical Technique

The procedure begins with an examination under anesthesia documenting patellar instability. The patella is visually divided into 4 vertical quadrants, and a laterally directed force is applied with the knee in full extension. Instability is then quantified and recorded based on the number of quadrants of lateral translation of the patella, with grade 4 representing full-width translation^{22,29} (Fig. 1). The ability to dislocate the patella is assessed by positioning the knee in full extension, then placing a laterally directed force on the patella. The knee is flexed to 60°, and the manual force is removed; if the patella remains locked in a dislocated position, it is considered dislocatable.²² The knee can then be extended to reduce the patella. Finally, the lateral retinacular structures are evaluated by attempting to passively evert the patella with the knee in full extension. If the patella cannot be everted to neutral, suggesting a negative passive patellar tilt, lateral release should be considered.²⁹

An esmarch is used to exsanguinate the extremity, and a tourniquet is inflated. A vertical incision is made along the anteromedial aspect of the proximal tibia, approximately 3-4 fingerbreadths below the joint line, and midway between the anterior tibial crest and posteromedial border of the tibia.

Once skin flaps have been raised, the tendons of the pes anserinus are palpable beneath the sartorius fascia. This fascia is then divided horizontally between the gracilis and semitendinosus. The semitendinosus is freed from the sartorial fascia and incised at its distal insertion, and a No. 2 nonabsorbable whipstitch suture is placed into the free tendon stump. All attachments between the semitendinosus and the medial head of the gastrocnemius are released. A tendon stripper is then used to harvest the semitendinosus proximally. In some patients we have elected to use semitendinosus allograft, to minimize postoperative discomfort and improve immediate postoperative function.

The tendon is cleared of any remaining muscular tissue, and the graft is folded in half. The folded graft is whipstitched together with a No. 2 suture for a distance of approximately 15 mm from the folded end, leaving two free suture limbs for later graft passage. The diameter of the folded graft is checked with a sizing guide, and usually measures 5-6 mm.

Following the hamstring harvest, a diagnostic arthroscopy is performed. This important step allows for assessment of any intra-articular abnormalities, including chondral injuries at the patellofemoral joint. Chondroplasty is performed when indicated, using a small shaver to remove any unstable cartilage flaps. Loose bodies are removed, and large osteochondral fragments can be reduced and fixed if technically feasible.²² If the preoperative examination demonstrated negative patellar tilt suggestive of tight lateral structures, a lateral release is then routinely performed. In patients with generalized ligamentous laxity, lateral release is not routinely necessary.²²

After completion of the arthroscopy, a 3-cm longitudinal incision is made at the medial aspect of the knee, approximately halfway between the adductor tubercle and the medial border of the patella. Skin flaps are raised, and with the knee in full extension, the dissection is carried laterally into the prepatellar bursa. A position of full extension facilitates exposure for the lateral portion of the surgical dissection. For the medial exposure, the knee is flexed to approximately 60° and the medial epicondyle is identified. This moving window of the skin incision allows for lateral exposure of the patella with the knee in full extension, and medial exposure of the femoral MPFL attachment with the knee in flexion. The single window is in contrast to previous techniques that involve 2 or more incisions for exposure.^{20,21,30,31}

The medial retinaculum is incised horizontally just distal to the VMO attachment onto the patella, a site which should approximate the proximal one-third of the patella. The incision is extended toward the adductor tubercle. This split in the retinaculum not only facilitates patellar exposure, but also allows for later imbrication of the VMO and medial soft tissues over the reconstructed MPFL graft. As opposed to other techniques that involve multiple incisions for exposure, the single window in the docking technique also facilitates imbrication of the medial retinaculum and VMO.

Preparation of the patella begins with the insertion of a 2.4-mm guide pin into the medial patella, precisely at the insertion site of the native MPFL. The pin is inserted to a depth of 20 mm, and directed lateral and slightly anterior to

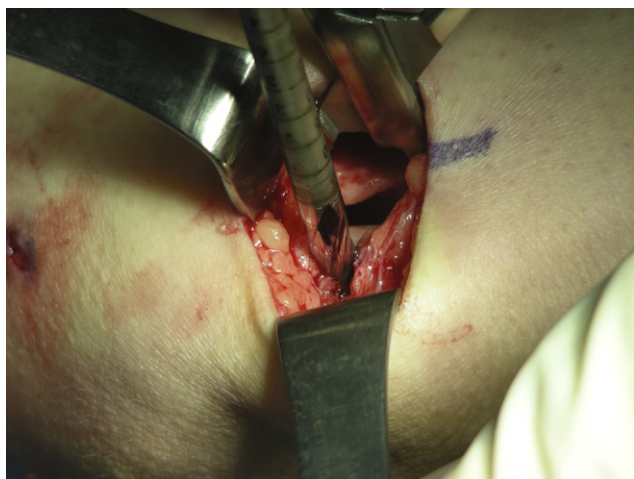

Figure 2 Drilling of the patellar docking tunnel over a guide pin. The width of the tunnel should match the width of the folded semitendinosus graft. (Reprinted with permission from Elsevier from G.D. Brown, C.S. Ahmad: The docking technique for medial patellofemoral ligament reconstruction. *Op Tech Orthop* 17:216-222, 2007.)

avoid penetration into the deep subchondral bone. The patellar docking tunnel is then drilled over the guide pin to a depth of 15-20 mm with a diameter equal to that of the graft (Fig. 2). In the setting of small-sized patellae, the depth of the tunnel may be decreased. If the graft diameter is too large, the graft can be trimmed to a smaller size and then accommodated in a smaller tunnel.

Once the docking tunnel has been created, 2 divergent holes are drilled from the base of the tunnel using a 2.4-mm pin with an eyelet (Arthrex, Naples, FL). One pin should be directed proximally and the other distally, maintaining a minimum 1 cm bone bridge between the pins at the lateral aspect of the patella (Fig. 3). The holes should be drilled

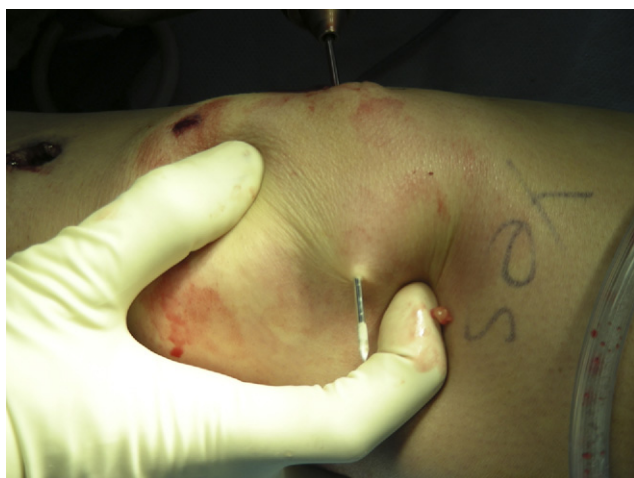

Figure 3 Insertion of the 2 divergent 2.4-mm pins (with eyelet) from the base of the patellar docking tunnel, exiting at the lateral aspect of the patella. (Reprinted with permission from G.D. Brown, C.S. Ahmad: The docking technique for medial patellofemoral ligament reconstruction. *Op Tech Orthop* 17:216-222, 2007.)

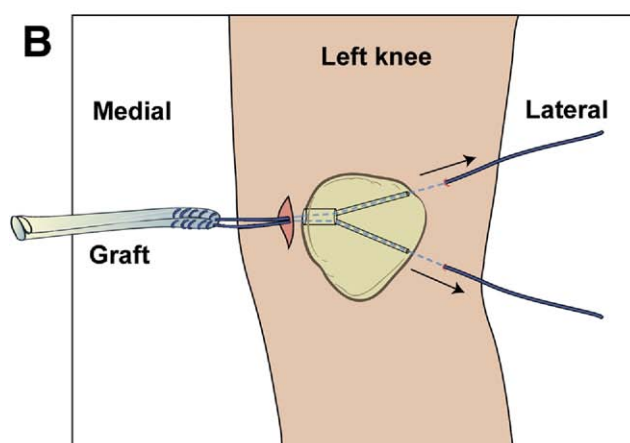
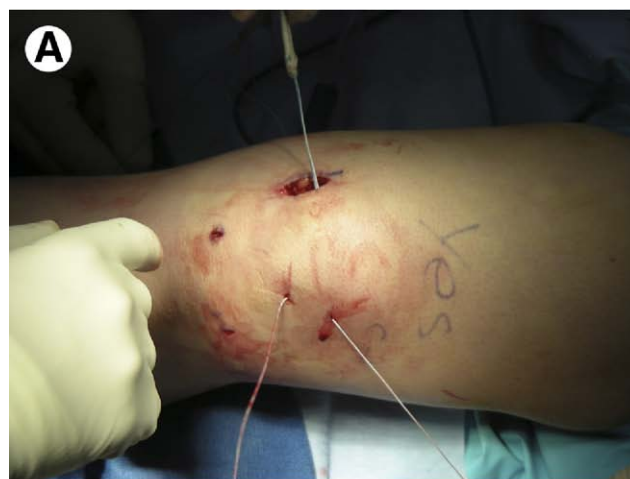

Figure 4 (A) Docking of the graft into the patellar tunnel. One limb of the whipstitch at the folded end of the graft has been passed into each of the 2.4-mm divergent holes. (B) Schematic diagram of the suture limbs passed through divergent holes at the base of the patellar docking tunnel, exiting laterally. (Reprinted with permission from Elsevier from G.D. Brown, C.S. Ahmad: The docking technique for medial patellofemoral ligament reconstruction. *Op Tech Orthop* 17:216-222, 2007.)

transversely in the plane of the patella, or directed slightly anterior to avoid cartilage penetration. After drilling, the pin exit position should be double-checked by placing a finger in the prepatellar bursa, and feeling each pin exiting on the anterior aspect of the lateral patella.^{2,22} The pins should traverse the patella and exit laterally by piercing the skin.

After each hole is drilled, the eyelet in the pin is used to pass a shuttle suture loop through the drill hole. Then, 1 free end of nonabsorbable suture from the mid portion of the folded graft is loaded into each shuttle loop and pulled through the drill holes to exit laterally (Fig. 4). The free ends are tensioned at the lateral patella to dock the graft within the patellar tunnel, until it is fully seated.²² The sutures exiting the lateral skin can then be retrieved into the skin incision with an arthroscopic probe placed in the prepatellar space.^{2,22} This step is facilitated by developing the prepatellar bursa all the way to the lateral patella before tunnel creation. Through the medial incision and the prepatellar space, the

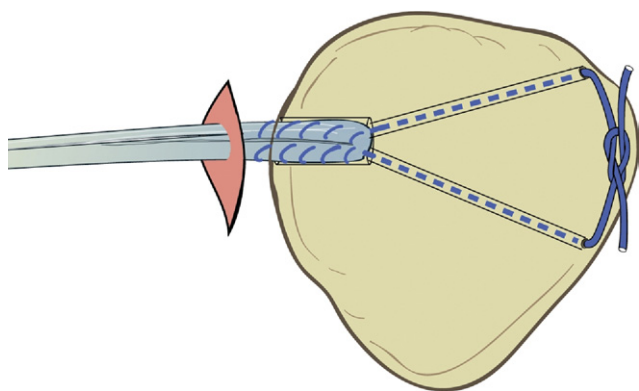


Figure 5 Suture limbs tied over the lateral patellar bone bridge, docking the graft securely within the patellar tunnel. (Reprinted with permission from Elsevier from G.D. Brown, C.S. Ahmad: The docking technique for medial patellofemoral ligament reconstruction. *Op Tech Orthop* 17:216-222, 2007.)

sutures are tied over the lateral bone bridge (Fig. 5). During this step, the patella can be displaced medially to simplify knot tying, and the tying fingers can be placed into the prepatellar space to appropriately tension the knot. Sutures should be cut short to minimize any knot prominence below the skin. Graft security should also be confirmed by pulling medially on the semitendinosus graft as it exits the docking tunnel.²²

An alternative to docking fixation is the use of cortical button fixation at the patella (Fig. 6). The benefit of this technique is a single tunnel across the patella, compared with the 2 small tunnels required in the docking procedure. The cortical button allows for full docking of the tendon within the tunnel, without relying on a bone bridge over which to tie the sutures.

The knee is flexed to 60°, and femoral preparation begins with insertion of a guide pin at the exact site of the MPFL attachment to the medial epicondyle. Referencing from the MCL attachment gives accurate and consistent results for tunnel placement.^{2,22} The guide pin is placed just proximal to

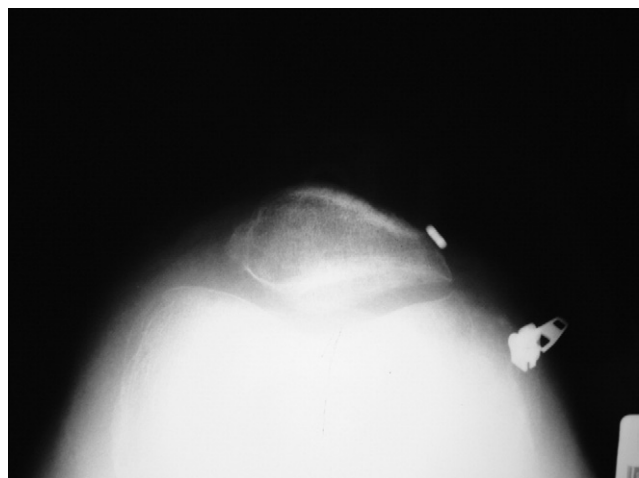


Figure 6 Sunrise radiograph demonstrating the use of a cortical button for patellar graft fixation.

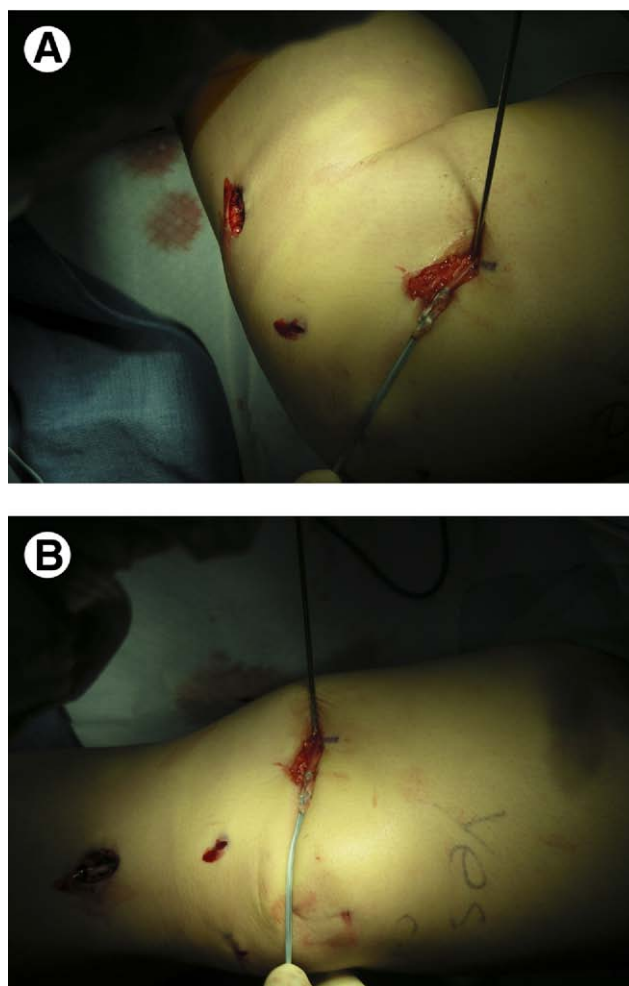


Figure 7 (A,B) Determination of graft isometry. The graft has been wrapped around the femoral guide pin, demonstrating little to no excursion with flexion (A) and extension (B) of the knee. (Reprinted with permission from Elsevier from G.D. Brown, C.S. Ahmad: The docking technique for medial patellofemoral ligament reconstruction. *Op Tech Orthop* 17:216-222, 2007.)

origin of the superficial MCL, and is directed slightly anterior and superior to avoid penetration of the posterior aspect of the medial femoral condyle during reaming.²² Once the pin has been placed, isometry is inspected by wrapping the graft around the pin with gentle tension. Then, with the patella held reduced within the trochlea, the knee is flexed and extended. If there is excursion of the graft more than 3 mm relative to the pin, the femoral pin site should be considered nonisometric (Fig. 7). In this case, the pin should be repositioned, and isometry rechecked until it is appropriately established.^{2,22} The pin often needs to be repositioned in a slightly more inferior and posterior position.²² Once the femoral isometric point has been confirmed, a 7 mm tunnel is drilled to a depth of 25 mm over the guide pin (Fig. 8).

The graft must next be appropriately tensioned, which is best performed with the knee flexed to 60°. At 60° of flexion the patella is fully engaged within the trochlea; its anatomic position is established by the geometry of the trochlea and patella, as well as the passive tension in the extensor mecha-

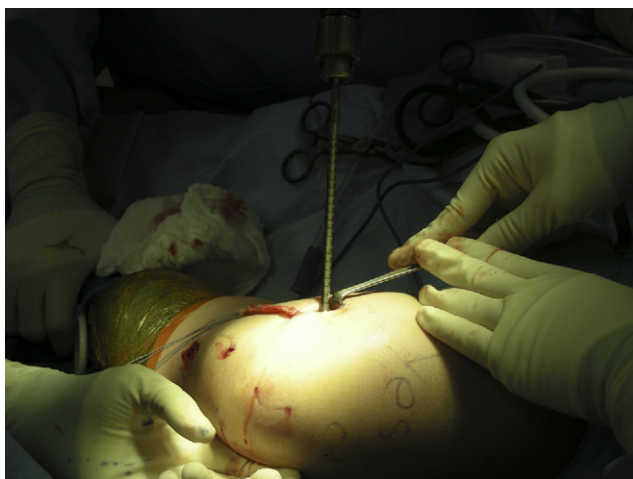

Figure 8 Drilling of the femoral tunnel over the guide pin. The tunnel should be directed slightly anterior and superior to avoid penetration of the medial femoral condyle. (Reprinted with permission from Elsevier from G.D. Brown, C.S. Ahmad: The docking technique for medial patellofemoral ligament reconstruction. *Op Tech Orthop* 17:216-222, 2007.)

nism.²² This anatomic position of the patella is therefore not influenced by the medially-directed force placed on the patella during tensioning the graft. The graft is provisionally positioned over the femoral tunnel and marked with a pen at the tunnel entrance. The 2 graft limbs are then whipstitched together with a No. 2 nonabsorbable suture for 20 mm from the anticipated site of entry into the femoral tunnel, starting at the marked point on the graft and working distally. Any excess graft can be carefully trimmed distal to the whipstitched suture.

The BioTenodesis (Arthrex) driver should be prepared with a 7 × 23 mm BioTenodesis (Arthrex) screw and a free looped No. 2 suture within the cannulation of the driver. The looped suture is placed around the graft at its distal extent. With tension held on the looped suture, the tip of the BioTenodesis driver can be used to directly control and tension the graft (Fig. 9). Using the tip of the driver, the graft is delivered under tension into the femoral tunnel. The screw is then advanced, keeping the tip of the driver in place to maintain appropriate graft tension and position. After the screw is seated, the driver is removed, leaving the looped suture exiting from the cannulation of the screw. The central sutures are tied to the sutures previously whipstitched into the graft, resulting in a combined suture anchor and interference screw construct^{2,22} (Fig. 10).

Tension and isometry should again be evaluated by ranging the knee from 0° to 110°, confirming proper tracking of the patella and ensuring that the reconstruction has not constrained motion.²² Finally, the VMO is imbricated by suturing it distally to the inferior medial retinaculum and the MPFL graft (Fig. 11). The previous horizontal incision in the medial retinacular tissue allows for inferior advancement of the VMO, restoring the intimate anatomic relationship between the MPFL and inferior quadriceps mechanism.⁶⁻⁸ This imbrication may also provide additional dynamic support to

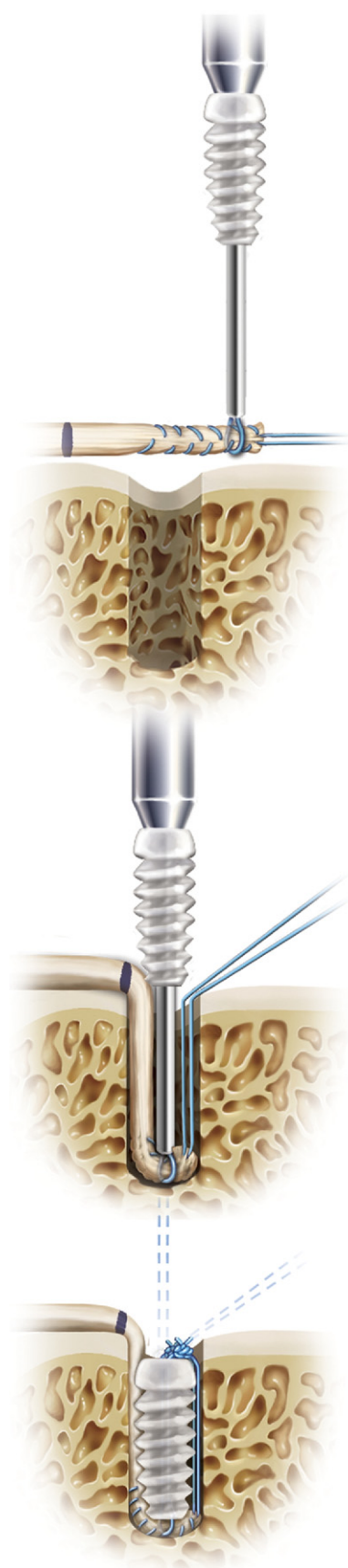

Figure 9 BioTenodesis screw insertion. The driver provides excellent control of graft tension during insertion, and the central suture allows for creation of an interference screw and suture anchor construct. (Reprinted with permission from Arthrex, Inc, Naples, FL).

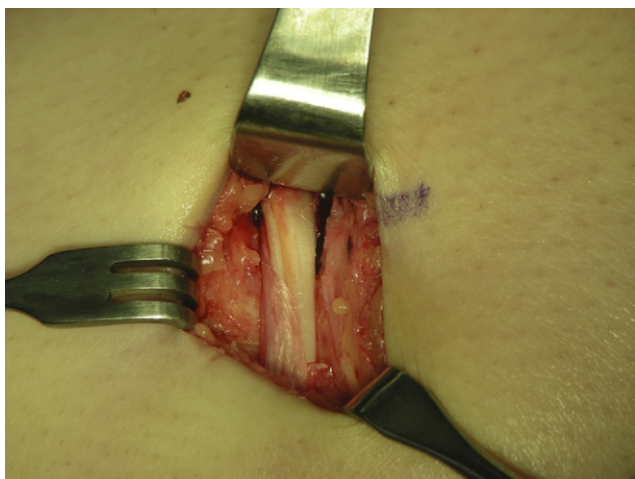


Figure 10 Final MPFL reconstruction with semitendinosus autograft, appropriately tensioned and securely fixed at the patella and femur. (Reprinted with permission from Elsevier from G.D. Brown, C.S. Ahmad: The docking technique for medial patellofemoral ligament reconstruction. *Op Tech Orthop* 17:216-222, 2007.)

the reconstruction,^{2,24} theoretically tensioning the graft when the VMO is activated.^{22,24} The wound is closed and a gentle compressive dressing is applied, after which the tourniquet is deflated.

Rehabilitation

Postoperatively, the knee is immobilized in full extension, allowing for immediate full weight-bearing without activation of the quadriceps.²² Weight bearing in extension continues for 4-6 weeks. A home program for quadriceps strengthening is also immediately initiated after surgery. At 2 weeks, formal physical therapy begins, including passive and active-assisted range of motion. At 6 weeks, the physical therapist is directed to begin more aggressive strengthening of the quadriceps and hamstrings, as well as the hip and core muscles. By 12 weeks, running and agility training are permitted, and a return to full athletics may be anticipated at 4 months.

Discussion

Many techniques have been described for reconstruction of the MPFL, each varying in the choice of graft, tunnel placement, and graft fixation.^{15,17-21,30-32,33} Overall success rates range from 83% to 93%.^{10,20,21} Deie et al first published a report of their MPFL reconstruction technique performed in a limited number of children,¹⁷ and later published expanded results in 43 adult and pediatric patients.¹⁸ In this technique, the semitendinosus was harvested proximally with an open tendon stripper, but left attached distally. Then, through a small slit in the posterior one-third of the superficial MCL, the semitendinosus was rerouted to the patella using the MCL as a pulley. The tendon was sutured into a patellar bone tunnel in skeletally mature patients, or sutured across the anterior surface of the patella in patients with open physes. VMO advancement was performed in all patients, with con-

comitant lateral release in 29 of 43. No recurrent dislocations were reported, although 4 knees had a sense of subluxation and a positive apprehension sign on postoperative physical examination.¹⁸ Gomes et al described a similar technique of reconstruction with semitendinosus autograft.²¹ One limb of the graft was passed through a patellar tunnel and sutured to the lateral retinaculum, while the second limb was passed into a tunnel drilled at the distal insertion of the adductor magnus. The femoral limb was pulled through the tunnel, looped under the adductor magnus, and sewn back onto itself. Good or excellent results were reported in 15 of 16

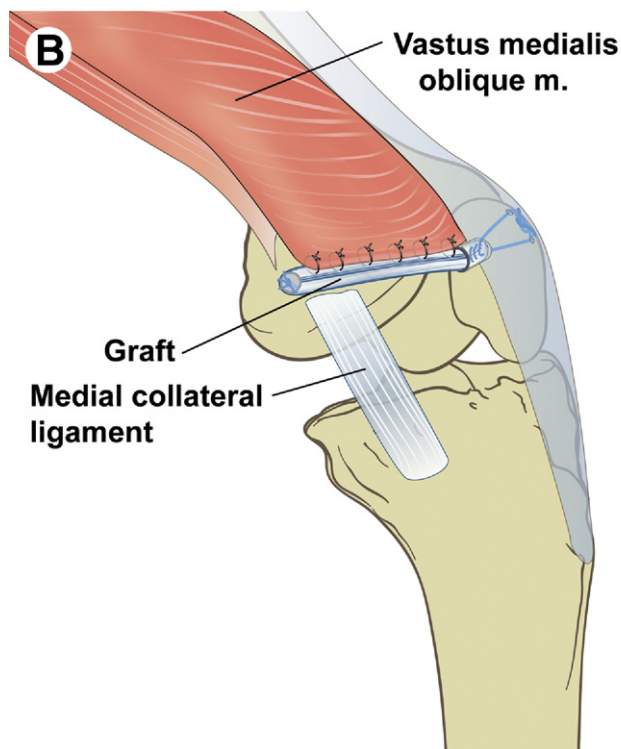
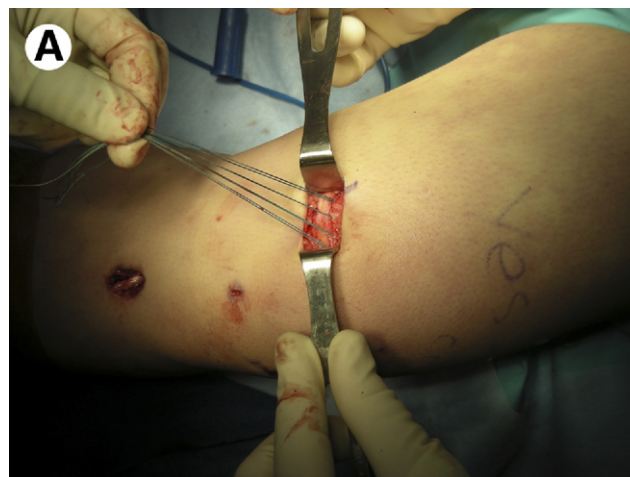

Figure 11 (A) Advancement of the vastus medialis obliquus over the reconstructed MPFL. (B) Schematic diagram of VMO imbrication to the final graft construct. (Reprinted with permission from Elsevier from G.D. Brown, C.S. Ahmad: The docking technique for medial patellofemoral ligament reconstruction. *Op Tech Orthop* 17:216-222, 2007.)

patients, with all showing negative apprehension, absence of patellofemoral pain, and normal patellar tracking. Overall, better results were demonstrated in patients with a normal Q angle.²¹

Schottle et al reported a 4-year follow-up on patients reconstructed with ipsilateral semitendinosus autograft and a suture anchor technique.²⁰ The graft was secured to the patella with 2 suture anchors placed at the superomedial border, and fixation at the femur was accomplished with a bone tunnel and interference screw at the adductor tubercle. Of the 15 knees (12 patients), 86% had good or excellent results. Mean Kujala scores increased significantly from 55.0 to 85.7, and patellar tilt decreased significantly from 11.3° to 9.2°. The authors reported 2 redislocations, and 3 patients with residual apprehension.²⁰

Nomura et al more recently described a hybrid MPFL reconstruction using doubled semitendinosus autograft.¹⁹ On the patellar side, the graft was sutured to the medial retinaculum after passing through an oblique bone tunnel exiting at the anterior patella. It was then secured to the anatomic femoral attachment site under minimum tension using a screw and spiked washer construct. The reconstruction was augmented with repair of native MPFL remnant. Good or excellent results were demonstrated at a 3-year follow-up in 83% of patients, with no redislocations or subluxations. Mean Kujala scores improved significantly from 56.3 to 96.0.¹⁹

LeGrand et al described a technique involving 2 separate patellar bone tunnels, entering medially and exiting anterolaterally.¹⁵ The hamstring graft was shuttled through each tunnel and looped over the lateral bone bridge, with the 2 free graft ends left exiting medially. The free ends were then secured at the femoral attachment site with an interference screw. The authors anecdotally reported no recurrent dislocations, no patellar fractures, and clinical results overall comparable to other published series and techniques.¹⁵ Carmont et al performed a similar procedure with semitendinosus or gracilis shuttled through full-width patellar bone tunnels, securing the graft at the femur with an interference screw.³⁰ Christiansen et al more recently described their technique using gracilis autograft, passed through two 4.5-mm drill holes in the patella.³¹ A bioabsorbable interference screw was again used at the femoral attachment site, with graft tensioning performed at 45° of knee flexion. Of 44 patients, 12 had concomitant tibial tubercle transfers. Overall 80% of patients felt that knee function improved postoperatively, with Kujala scores increasing from 46 to 84. The authors reported 1 redislocation and 3 subluxations. Four patients complained of chronic pain, all of whom demonstrated cartilage injury at the time of the surgical reconstruction.³¹

In summary, available reports in the literature vary in terms of graft selection, tunnel location, and means of fixation. Previously published techniques do not, however, attempt to verify functional isometry of the graft at the time of surgery. The docking technique described in the current review provides an accurate and secure reconstruction of the MPFL, ensuring restoration of ligament isometry. On the femoral side, preliminary insertion of the guide pin at the femoral attachment site allows for accurate determination

of isometric tunnel placement. In cases of nonisometric placement, the pin can be easily repositioned without further disruption of the medial bony and soft-tissue structures. The use of a small and single patellar tunnel minimizes the presence of a stress riser and limits the potential for iatrogenic patella fracture. Furthermore, the docking of the looped semitendinosus graft permits tendon-bone healing within the tunnel, as opposed to techniques that rely on anchor or suture fixation at the margin of the patella.^{20,34} The use of 2.4-mm guide pins to drill the exit tunnels in the patella limits the risk of penetration at the articular surface, as these pins are small and easily controlled. The BioTenodesis system affords excellent control of the graft during insertion, and the additional central suture allows for creation of a combined suture anchor and interference screw construct. Finally, imbrication of the VMO restores the native anatomy of the medial soft tissues, lends support to the reconstructed MPFL, and may provide dynamic tension to the reconstruction.

Recently, Ahmad et al published a retrospective review of 20 patients with MPFL reconstruction using the docking technique described.²² Concomitant lateral release was performed in 12 patients, with chondroplasty performed in 7. At an average follow-up of 31 months, physical examination in all patients was negative for apprehension. No recurrent dislocations or subluxations were reported. Preoperative mean lateral quadrant translation was 3.5 with a soft endpoint, compared with 1.8 with a firm endpoint at the most recent postoperative follow-up. International Knee Documentation Committee subjective evaluation, Tegner, Lysholm, and Kujala scores all showed statistically significant improvement from preoperative values. All patients returned to preoperative levels of function and athletics after surgery.²²

Conclusions

The management of patellar instability has recently advanced, with an improved understanding of the critical role of the MPFL, along with the development of novel techniques for ligament reconstruction. The docking technique for MPFL reconstruction offers several technical advantages, including anatomically accurate reconstruction, ease of confirmation of graft isometry, and simplicity of graft tensioning and fixation. Biomechanically, the femoral fixation provides a combined interference screw and suture anchor construct. Furthermore, imbrication of the VMO and medial retinaculum may contribute additional dynamic support to the medial soft-tissue reconstruction. The docking technique offers a simplified accurate approach to MPFL reconstruction, with consistently favorable postoperative results in the management of patellar instability.

References

1. Beasley LS, Vidal AF: Traumatic patellar dislocation in children and adolescents: Treatment update and literature review. *Curr Opin Pediatr* 16:29-36, 2004
2. Brown GD, Ahmad CS: The docking technique for medial patellofemoral ligament reconstruction. *Op Tech Orthop* 17:216-222, 2007
3. Ahmad CS, Stein BE, Matuz D, et al: Immediate surgical repair of the

- medial patellar stabilizers for acute patellar dislocation. A review of eight cases. *Am J Sports Med* 28:804-810, 2000
4. Nomura E: Classification of lesions of the medial patello-femoral ligament in patellar dislocation. *Int Orthop* 23:260-263, 1999
 5. Sanders TG, Morrison WB, Singleton BA, et al: Medial patellofemoral ligament injury following acute transient dislocation of the patella: MR findings with surgical correlation in 14 patients. *J Comput Assist Tomogr* 25:957-962, 2001
 6. Conlan T, Garth WP Jr, Lemons JE: Evaluation of the medial soft-tissue restraints of the extensor mechanism of the knee. *J Bone Joint Surg Am* 75:682-693, 1993
 7. Desio SM, Burks RT, Bachus KN: Soft tissue restraints to lateral patellar translation in the human knee. *Am J Sports Med* 26:59-65, 1998
 8. Hautamaa PV, Fithian DC, Kaufman KR, et al: Medial soft tissue restraints in lateral patellar instability and repair. *Clin Orthop Relat Res* 349:174-182, 1998
 9. Amis AA, Firer P, Mountney J, et al: Anatomy and biomechanics of the medial patellofemoral ligament. *Knee* 10:215-220, 2003
 10. Nomura E, Horiuchi Y, Kihara M: Medial patellofemoral ligament restraint in lateral patellar translation and reconstruction. *Knee* 7:121-127, 2000
 11. Smirk C, Morris H: The anatomy and reconstruction of the medial patellofemoral ligament. *Knee* 10:221-227, 2003
 12. Sallay PI, Poggi J, Speer KP, et al: Acute dislocation of the patella. A correlative pathoanatomic study. *Am J Sports Med* 24:52-60, 1996
 13. Tuxoe JI, Teir M, Winge S, et al: The medial patellofemoral ligament: A dissection study. *Knee Surg Sports Traumatol Arthrosc* 10:138-140, 2002
 14. Nomura E, Horiuchi Y, Inoue M: Correlation of MR imaging findings and open exploration of medial patellofemoral ligament injuries in acute patellar dislocations. *Knee* 9:139-143, 2002
 15. LeGrand AB, Greis PE, Dobbs RE, et al: MPFL reconstruction. *Sports Med Arthrosc* 15:72-77, 2007
 16. Nomura E, Inoue M: Surgical technique and rationale for medial patellofemoral ligament reconstruction for recurrent patellar dislocation. *Arthroscopy* 19:E47, 2003
 17. Deie M, Ochi M, Sumen Y, et al: Reconstruction of the medial patellofemoral ligament for the treatment of habitual or recurrent dislocation of the patella in children. *J Bone Joint Surg Br* 85:887-890, 2003
 18. Deie M, Ochi M, Sumen Y, et al: A long-term follow-up study after medial patellofemoral ligament reconstruction using the transferred semitendinosus tendon for patellar dislocation. *Knee Surg Sports Traumatol Arthrosc* 13:522-528, 2005
 19. Nomura E, Inoue M: Hybrid medial patellofemoral ligament reconstruction using the semitendinosus tendon for recurrent patellar dislocation: Minimum 3 years' follow-up. *Arthroscopy* 22:787-793, 2006
 20. Schottle PB, Fucentese SF, Romero J: Clinical and radiological outcome of medial patellofemoral ligament reconstruction with a semitendinosus autograft for patella instability. *Knee Surg Sports Traumatol Arthrosc* 13:516-521, 2005
 21. Gomes JL, Marczyk LR, Cesar PC, et al: Medial patellofemoral ligament reconstruction with semitendinosus autograft for chronic patellar instability: A follow-up study. *Arthroscopy* 20:147-151, 2004
 22. Ahmad CS, Brown GD, Shubin Stein B: The docking technique for medial patellofemoral ligament reconstruction: Surgical technique and clinical outcome. *Am J Sports Med* 37:2021-2027, 2009
 23. Hinton RY, Sharma KM: Acute and recurrent patellar instability in the young athlete. *Orthop Clin North Am* 34:385-396, 2003
 24. Nomura E, Inoue M, Osada N: Anatomical analysis of the medial patellofemoral ligament of the knee, especially the femoral attachment. *Knee Surg Sports Traumatol Arthrosc* 13:510-515, 2005
 25. Mountney J, Senavongse W, Amis AA, et al: Tensile strength of the medial patellofemoral ligament before and after repair or reconstruction. *J Bone Joint Surg Br* 87:36-40, 2005
 26. Hamner DL, Brown CH Jr, Steiner ME, et al: Hamstring tendon grafts for reconstruction of the anterior cruciate ligament: Biomechanical evaluation of the use of multiple strands and tensioning techniques. *J Bone Joint Surg Am* 81:549-557, 1999
 27. Krushinski EM, Brown JA, Murthi AM: Distal biceps tendon rupture: Biomechanical analysis of repair strength of the Bio-Tenodesis screw versus suture anchors. *J Shoulder Elbow Surg* 16:218-223, 2007
 28. Idler CS, Montgomery WH 3rd, Lindsey DP, et al: Distal biceps tendon repair: A biomechanical comparison of intact tendon and 2 repair techniques. *Am J Sports Med* 34:968-974, 2006
 29. Kolowich PA, Paulos LE, Rosenberg TD, et al: Lateral release of the patella: Indications and contraindications. *Am J Sports Med* 18:359-365, 1990
 30. Carmont MR, Maffulli N: Medial patellofemoral ligament reconstruction: A new technique. *BMC Musculoskelet Disord* 8:22, 2007
 31. Christiansen SE, Jacobsen BW, Lund B, et al: Reconstruction of the medial patellofemoral ligament with gracilis tendon autograft in transverse patellar drill holes. *Arthroscopy* 24:82-87, 2008
 32. Scheck EJ, Burks RT: Medial patellofemoral ligament reconstruction using a hamstring graft. *Oper Tech Sports Med* 9:169-175, 2001
 33. Farr J, Schepsis AA: Reconstruction of the medial patellofemoral ligament for recurrent patellar instability. *J Knee Surg* 19:307-316, 2006
 34. Drez D Jr, Edwards TB, Williams CS: Results of medial patellofemoral ligament reconstruction in the treatment of patellar dislocation. *Arthroscopy* 17:298-306, 2001